

## EVALUATION OF A TRAINING COURSE ON OPEN VASCULAR SURGICAL TECHNIQUES IN AORTOILIAC PATHOLOGY - 5 YEARS OF EXPERIENCE

BOGDAN STANCU<sup>1</sup>, FLORIN BETEG<sup>2</sup>, AUREL MIRONIUC<sup>1</sup>,  
AUREL MUSTE<sup>2</sup>, CLAUDIA GHERMAN<sup>1</sup>

<sup>1</sup>2nd Department of General Surgery, Iuliu Hatieganu University of Medicine and Pharmacy, Cluj-Napoca, Romania

<sup>2</sup>4th Clinical Department, Faculty of Veterinary Medicine, University of Agricultural Sciences and Veterinary Medicine, Cluj-Napoca, Romania

### Abstract

**Introduction.** The aim of this prospective study was to assess the efficacy of a vascular surgery course (2008-2012), and to verify the viability and the feasibility of vascular anastomoses.

**Material and method.** The vascular surgical techniques performed simultaneously on pigs were: enlargement prosthetic angioplasty, abdominal aortic interposition graft and aortoiliac bypass. The endpoints of the study were the surgical skills and the technical quality, assessed on a scale ranging from 1 (satisfactory) to 3 (very good) for our participants.

**Results.** A significant improvement in vascular surgical skills tasks was observed during the study years and we also found a significant statistical association between the quality of the suture and the surgical technique used (Kendall coefficient=0.71,  $p=0.001<0.05$ ).

**Conclusions.** Our course contributed to the improvement of the technical vascular surgical skills of the operator teams, reproducing in vivo, in pigs, the intraoperative environment of human patients.

**Keywords:** Vascular surgery training, quality of vascular suture, aortoiliac pathology.

### Introduction

The aim of this prospective study was to assess the efficacy of a vascular surgery course (2008-2012), and to examine the viability and the feasibility of the vascular anastomoses.

In this study, vascular surgery techniques were performed on 21 *in vivo* animal models as part of a postgraduate course from the vascular surgery curriculum developed at the University of Medicine and Pharmacy "Iuliu Hatieganu" Cluj-Napoca for upper-level vascular surgery residents.

Before this course the residents completed an *ex vivo* vascular sutures postgraduate course on pig aortas, veins

and different types of prostheses in laboratory conditions.

Our hypothesis was that the practice of vascular anastomotic techniques using animal models would objectively improve the surgical residents' technical skills.

Vascular surgeons perform numerous highly sophisticated, expensive and delicate surgical procedures. Due to restrictions in training time, new concepts including alternative environments for the training and assessment of surgical skills are required. Over the past decades, animal models, training on simulators and synthetic models have become more sophisticated and lifelike [1,2].

### Material and method

The vascular surgical techniques performed simultaneously on pigs were: enlargement prosthetic angioplasty, abdominal aortic interposition graft and

Manuscript received: 15.02.2015

Received in revised form: 10.03.2015

Accepted: 17.03.2015

Address for correspondence: bstancu7@yahoo.com

aortoiliac bypass. The endpoints of the study were the surgical skills and the technical quality, evaluated on a scale ranging from 1 (satisfactory) to 3 (very good) for our participants. The results were introduced into a Microsoft Excel database and analyzed from the statistical point of view using Fisher's test, the Cramer coefficient and Kendall's correlation coefficient.

We assessed many parameters during the study including the type of anesthesia, the type of suture, the type of prosthesis, the surgical technique, the vascular suture, the survival rate at 7 days and 1 month and postoperative death.

The analytical retrospective study was performed during 5 years (2008 – 2012), at the Faculty of Veterinary Medicine from Cluj-Napoca, during which time a number of 21 surgical interventions were carried out on common race pigs (Suis scrofa), weighing approximately 30-40 kg, because of the existence of a good anatomical analogy from the point of view of the structure and diameters of the aortic system.

We used synthetic prostheses (Terom, Dacron, GoreTex/PTFE) and double needle monofilament polypropylene sutures 5.0 and 6.0. Before each arterial clamping I.V. 2500 UI of Heparin were injected.

We mention that all the experiment animals from this study received i.v. a single dose of antibiotics Ceftriaxonum (Cefort®, 1g), one hour before the surgical intervention, without further administration.

During the experiment the pigs were maintained in standard laboratory conditions, controlled light 12 hours a day, and controlled temperature of 22°C, fed with a standard laboratory diet, which was stopped 24 hours before the surgical intervention.

We performed the preoperative preparation of the experience animals, preanesthesia and anesthesia, achieving the proposed vascular surgical interventions, the postoperative evolution of the pigs, and at the end of the study, depending on their survival, the death by induction of the animals.

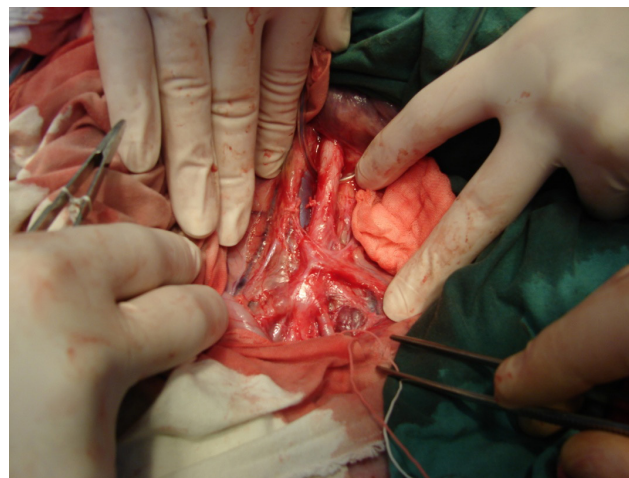
The surgical interventions required general anesthesia with Ketamine i.v. or orotracheal intubation.

## Results

The surgical interventions were carried out by 2 or more teams at the same time. Each team had 2 or 3 members. Table I contains the number of pigs for every year. The pigs weighed between 40 and 60 Kg.

The pig's aortic system is similar to the human one, with only one major difference, that in the pig the abdominal aorta splits directly into 4 iliac arteries (2 internal and 2 external iliac arteries) and the median sacral artery, while in humans the abdominal aorta splits initially into 2 common iliac arteries and the median sacral artery, these being followed by subsequent splitting on each side into internal and external iliac arteries.

The general anesthesia was carried out by the veterinarian as follows: by orotracheal intubation using



**Figure 1.** Abdominal aorta in the pig.

Isofluran (10 cases) and by using Ketamin intravenously (11 cases). For induction we used a concentration of 3%, and for maintaining the anesthesia we used a concentration of 2%. For general intravenous anesthesia we used microdoses of Ketamin, 1mg/body kg at every 10 minutes. The pigs which were anesthetized with isofluran were monitored from the respiratory and cardiovascular point of view.

The intervention began by a longitudinal xiphopubic incision, followed by the dissection of the subcutaneous plane and the incision of the linea alba, and the opening of the abdominal cavity. We took the bowel out of the abdominal cavity, protected by 3 textile compresses soaked in warm saline solution.

Then, the intervention consisted of the incision of the posterior peritoneum and the dissection of the abdominal aorta and of the iliac arteries, which were hanged using silastic rings.

In the cases where we used a knitted prosthesis (Dacron, Terom) we punctured the aorta and we collected unheparinized blood, the prosthesis being then precoagulated with this blood.

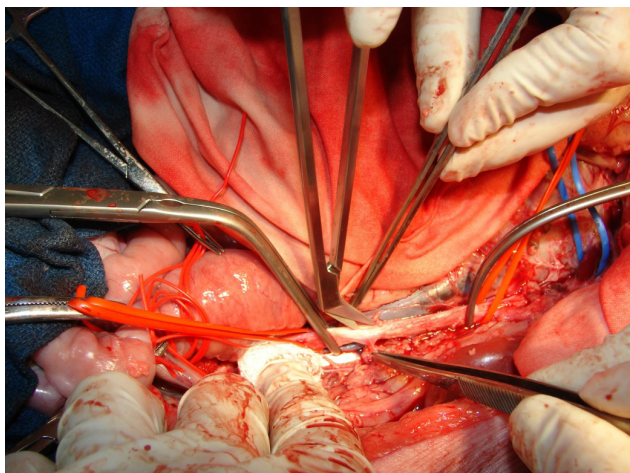
After establishing the level of the anastomosis we administered intravenously 2500 UI of Heparin. After the clamping of the abdominal aorta we performed the arteriotomy with blade no. 11 of the scalpel and then we made the enlargement of the arteriotomy with Potts scissors.

The first time we achieved the technique of enlargement angioplasty by suturing a synthetic patch on the abdominal aorta, using continuous suture with double needle monofilament polypropylene 5.0 and 6.0.

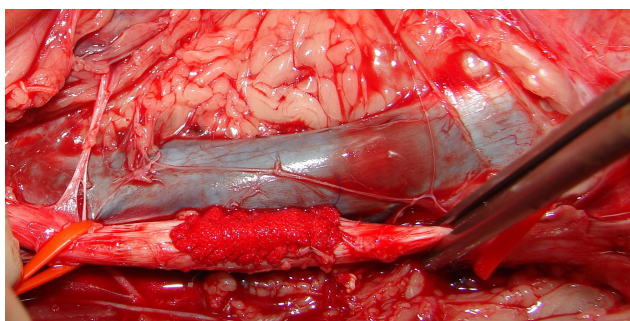
Later the aorta was declamped to see the viability of the patch, the hemorrhage from the suture, if any, applying separate supplementary sutures in those cases.

The surgical intervention continued with the second technique, abdominal aortic synthetic interposition graft,



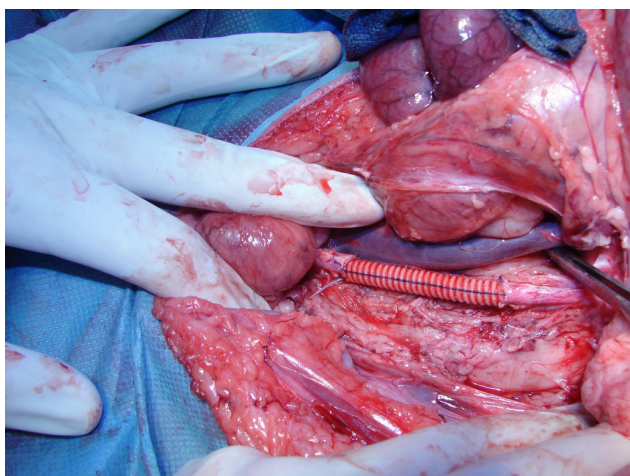


**Figure 2.** The arteriotomy with Potts scissors.



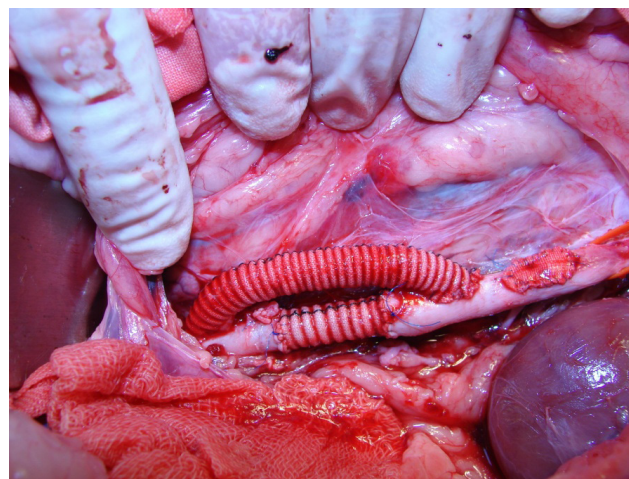
**Figure 3.** Enlargement angioplasty with synthetic patch on the abdominal aorta.

in order to achieve the end to end anastomoses using the simple or “parachute” continuous suture. We re-clamped the aorta and we completely sectioned transversely the aorta, followed by the setting of prosthesis at this level by end to end suture, and the declamping of the aorta and watching the functionality of the anastomosis. This was achieved by the staging of the prosthesis at this level by an end to end suture, and then the declamping of the aorta and observing the functionality of the anastomosis.



**Figure 4.** Synthetic interposition graft at the abdominal aorta level.

The third surgical technique performed was the aorto-iliac bypass. We reclamped the abdominal aorta and one of the iliac arteries. The residents cut the prosthesis at one end in “Italic S” shape. Then they performed the arteriotomy and the end to side anastomosis using continuous simple or “parachute” suture with monofilament polypropylene 6.0. After they finished the arterial sutures they removed the arterial clamps and checked if there were hemorrhages or not at the place of the sutures and if the arteries were pulsating.



**Figure 5.** Aorto - iliac bypass.

The type of suture on vascular anastomoses was in 10 cases a simple continuous suture and in 11 cases the parachute continuous suture.

We used synthetic prosthesis (Terom, Dacron, GoreTex/PTFE) and double needle monofilament polypropylene suture 5.0 and 6.0.

The surgical interventions were finished by the suture of the posterior peritoneum and the return of the bowel into the abdominal cavity, and the suture of the anatomical layers of the anterior abdominal wall.

Later, we performed the euthanasia of the pigs, and we harvested sections at different levels of the abdominal aorta, iliac arteries, prosthesis and anastomoses, checking the reliability, the resistance of the anastomoses and of the prosthesis, for their histopathological analysis.

The operated subjects did not receive postoperative anticoagulant or antibiotic medication.

We did not encounter major haemorrhages after removing the arterial clamps, which proved the tightness of the vascular sutures. In some cases we needed to apply supplementary suture threads on the anastomoses for minor leakage.

In only one case did we encounter the accidental lesion of the inferior vena cava during the dissection of the abdominal aorta, which was solved by suture. There were 3 other cases of lumbar veins lesion during the dissection of the abdominal aorta and we managed to perform the haemostasis. No intraoperative deaths were recorded.

During one surgical intervention we encountered as an intraoperative complication the apnea caused by the intravenous overdose of Ketamine, a situation which was overcome by orotracheal intubation of the subject, with restart of the spontaneous breathing until the end of the surgical intervention.

Another important parameter for the evolution of the subjects was the total time of the surgical intervention which was between 4 and 6 hours, because all 3 types of vascular surgical techniques were performed in each case.

Giving that the pigs did not receive postoperative anticoagulant medication, we had 6 survivals at 7 days, 1

survival at 1 month and 14 deaths.

A significant improvement in vascular surgical skills tasks was observed during the year.

We assessed the quality of the vascular suture and the surgical technique of each intervention: satisfactory [1], good [2] and very good [3].

We did not find significant statistical differences between the frequencies of the type of prosthesis depending on the type of suture. There was a tendency to be significant (Fisher's exact test, Test statistics=4.48,  $p=0.09>0.05$ )

There was a good positive association, statistically significant, between the quality of the suture and the

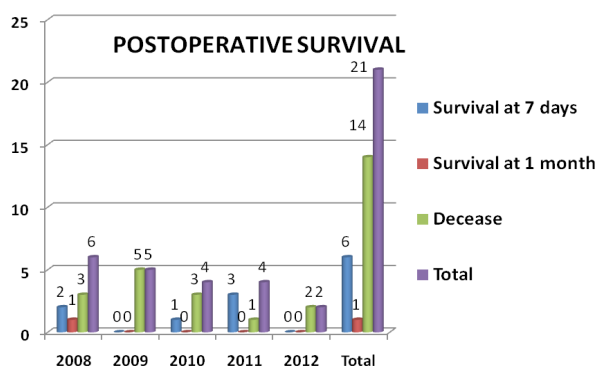


Figure 6. Postoperative survival rate.

Table I. The parameters assessed in the study for all the subjects.

Year	No	Type of anesthesia	Type of suture	Type of prosthesis	Surgical technique	Vascular suture	Survival at 7 days	Survival at 1 month	Postop. Decease
2008	1	K	S	T	1	1	N	N	Y
2008	2	I	S	T	2	2	N	N	Y
2008	3	K	S	T	1	1	N	N	Y
2008	4	K	S	G	3	2	Y	N	N
2008	5	K	S	T	2	2	Y	N	N
2008	6	I	S	D	3	2	N	Y	N
2009	7	K	S	D	2	2	N	N	Y
2009	8	I	S	D	3	3	N	N	Y
2009	9	K	S	D	3	3	N	N	Y
2009	10	I	S	D	3	2	N	N	Y
2009	11	K	S	D	3	3	N	N	Y
2010	12	K	P	D	2	2	N	N	Y
2010	13	I	P	D	3	3	Y	N	N
2010	14	K	P	D	3	2	N	N	Y
2010	15	I	P	D	3	3	N	N	Y
2011	16	K	P	D	3	3	Y	N	N
2011	17	I	P	D	2	2	Y	N	N
2011	18	K	P	D	3	2	N	N	Y
2011	19	I	P	D	3	3	Y	N	N
2012	20	I	P	G	2	2	N	N	Y
2012	21	I	P	D	3	3	N	N	Y

K=Ketamine, I=Isoflurane, S=simple, P=Parachute, t=Terom, D=Dacron, G=GoreTex, N=No, Y=Yes

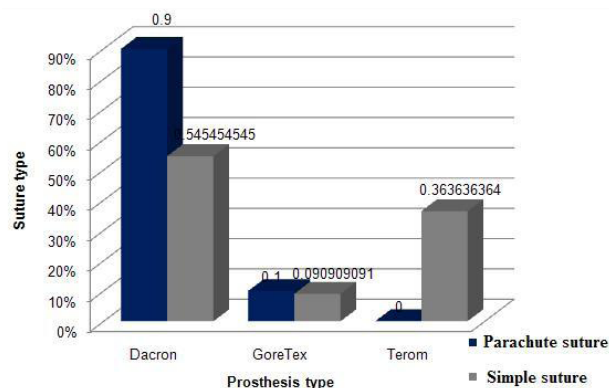


Figure 7. Correlations between the type of suture and the type of prosthesis.

surgical technique (Kendall's correlation coefficient=0.71,  $p=0.001<0.05$ ).

They also improved in the graft patch orientation, use of a needle holder, use of forceps needle angle and needle transfer. They also improved in obtaining an appropriate bite, creating appropriate spacing, suture management and knot tying. We also noticed an improvement in time and motion, instrument handling and knowledge of specific procedure. Observance of tissues was also improved. Thus residents showed a statistically significant improvement in their surgical performance during this postgraduate course.

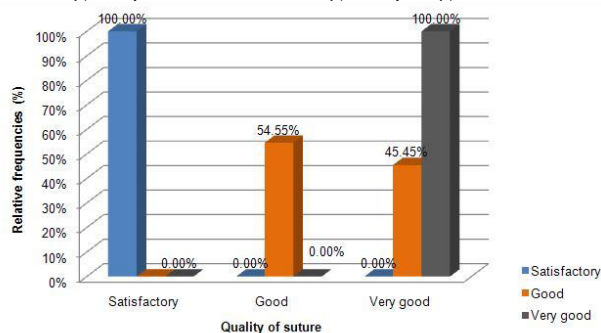


Figure 8. Quality of the suture.

## Discussion

Atherosclerotic diseases are very frequent in the general population, a fact which leads to higher financial and social costs of treatment, so that the evaluation of the patient must be carried out by a competent medico-surgical team, with good training for those diseases, and the indication for surgical treatment must not be delayed until the emergence of trophic lesions [3].

The intraoperative hemorrhagic complications encountered, such as the accidental lesion of the lumbar veins and the accidental lesion of the inferior vena cava respectively have increased the difficulty of those surgical interventions and were solved successfully by the residents under the supervision of the course coordinators. Another important factor reflected in the postoperative evolution of the subjects was the total time of the surgical intervention which was over 4 hours for each subject, because of the performing of 3 types of vascular techniques.

The positive aspects of this study were that we did not have any intraoperative death, the arteries presented pulsations downstream and upstream from the anastomoses and the teams had the possibility to achieve all the surgical techniques proposed and to improve their vascular surgical skills.

The negative aspects were that the experiment animals did not receive postoperative anticoagulant medication and antibiotics. Another aspect was that not all of the subjects were monitored from the cardiovascular and respiratory point of view, this being possible only for those who were anaesthetized with Isoflurane, because we had

only one anesthesia machine, and the study was developed with two surgical interventions at the same time. In those experimental conditions a survival of 28.5% at 7 days is acceptable.

The cost of aorto-iliac surgery is very high because it uses expensive synthetic prostheses, while at the femoro-popliteal level the autologous great saphenous vein is mainly used, which makes the infrailiac surgery more affordable and more permissive, with a larger number of cases operated than aorto-iliac surgery.

Terom knitted prostheses, of Romanian origin, need precoagulation with unheparinised blood, but their higher porosity made us use them less frequently. Dacron prostheses are also knitted prostheses, but they can be collagenated, which gives them impermeability, whereas the GoreTex/ePTFE prostheses (Teflon) are casted and repellent.

The Dacron prosthesis is preferred in aortic reconstruction, having a very good stability and durability in time, being used in our study in 76.2% of the subjects. The ePTFE prosthesis resists at higher external compressions, has a higher thrombo-resistance, resistance against deformation and aneurysmal dilation, but they are much more expensive.

Because of the failure rate of the anastomoses using synthetic prostheses, research is under development, in order to create new synthetic materials to improve the reliability of the prosthesis [4].

Even if initially we used simple continuous suture on the vascular anastomoses, in recent years we performed the "parachute" continuous suture in 52.4% of subjects, because it may be performed quickly and because of a much better juxtaposition of the anastomotic bottoms. Thereby we found a good positive association, statistically significant, between the quality of the suture and the surgical technique [5].

Arteriography and Doppler ultrasound during and after the intervention would have been useful in order to assess the efficiency of surgical vascular techniques, comparatively with the angiography by MRI or the CT angiography, which are relatively expensive investigations [6].

The field of surgery has dramatically changed, with the advent of laparoscopy, critical care, bariatric surgery, endovascular surgery, and organ transplantation. Surgical training, however, has remained largely unchanged, with the requirement for large volumes of cases to assure competency. Simulation, the act of mimicking a real person, object, event, or process, provides the ideal learning environment to allow the trainee to become proficient by deliberate repetitive practice in a protected environment [7].

Simulation can be designed for all levels of individual learners, giving them the opportunity to practice specific skills at their own pace. Simulation also offers training



flexibility because no large ancillary staff is needed, as is the case of animal “wet labs”. Because of these strengths, simulation is becoming the new cornerstone of health professions education, patient safety, and error reduction [8].

Recognizing the power of simulation methods and techniques, the American College of Surgeons has developed an accreditation program for surgical simulation programs, anticipating the increasing need for simulation in residency training [9].

With the advent of this new educational technology, in other countries, residency programs have begun developing curriculums around the use of simulators. For instance, as part of their resident assessment, the Department of Surgery at the University of Toronto developed a 2-hour, 8-station evaluation of resident technical skills called the OSATS [10]. (10)

Cardiovascular surgeons have begun to use technical simulators to train residents and fellows. Fann et al have developed and tested a simulation based curriculum for first-year cardiothoracic residents. They used both a porcine heart wet lab simulator and a lower fidelity synthetic anastomotic simulator. Thirty-three residents participated in a 4-hour session supervised by 6 to 7 attending surgeons for 8 to 9 residents. Anastomotic skills were assessed in person and by blinded observers reviewing video on a standardized 3-point rating scale. (11,12)

Anastomotic performance improved since simulation training. At 6 months, residents noted that the session was helpful, but only about half continued to practice.

The use of a porcine model had some difficulties and costs associated with maintaining live animals but with the help of our colleagues from the Faculty of Veterinary Medicine we managed to overcome all those technical problems.

The costs of using live animals (\$100/pig) were significantly lower in our study than for the development for other training programs. Consumable supplies were only suture materials and the cost was \$200. As an example a set of 4 trainers in the USA (angioplasty, aortic aneurysm, femoral-popliteal bypass, and femoral-tibial bypass) cost \$2600 in 2010. Replacement femoral-popliteal blood vessels are approximately \$30 for 6 vessels, the aortic aneurysm replacement is \$35, and 3 replacement carotid vessels were \$95. (13,14)

Our hypothesis that the practice of anastomotic techniques using the vascular surgical training would improve technical skills was validated, as judged by objective assessments. Overall surgical skills did improve, and most subsets of each evaluation scale also showed statistically significant improvement. Practice using *in vivo* models led to measurable improvement in vascular anastomotic technique in general surgery residents.

The final “animal-to-human” translation of this

project would be if the residents’ performance in the operating room improved as well, but this is beyond the scope of our project.

This project is a positive first step in the design of a simulation-based vascular surgery curriculum for surgical residents and may potentially become valuable preparation for the operating room.

## Conclusions

Our course contributed to the improvement of the technical vascular surgical skills of the operator teams, reproducing *in vivo*, in pigs, the intraoperative environment of human patients.

The intraoperative hemorrhagic complications encountered, such as the accidental lesion of lumbar veins and the lesion of the Inferior Vena Cava respectively have increased the difficulty of those interventions and they were handled successfully by the participants under the supervision of their coordinators.

This experimental study proved the functionality of the anastomoses achieved, whereas in all cases the arteries presented palpable pulsations both on the prosthesis and pre and post - anastomoses. All the participants achieved the proposed objectives, performing all of the vascular surgical techniques offered.

With regard to the current curriculum of surgical trainees in Romania, basic and advanced vascular surgery courses should be considered as a potential valuable part of their surgical education, because of the possible shortening of the learning curve for the vascular surgical techniques in hospitals.

## References

1. Sigounas VY, Callas PW, Nicholas C, Adams JE, Bertges DJ, Stanley AC, et al. Evaluation of simulation-based training model on vascular anastomotic skills for surgical residents. *Simul Healthc*. 2012;7(6):334-338.
2. Bath J, Lawrence P, Chandra A, O’Connell J, Uijtdehaage S, Jimenez JC, et al. Standardization is superior to traditional methods of teaching open vascular simulation. *J Vasc Surg*. 2011;53:229-235.
3. Robinson WP, Schanzer A, Cutler BS, Cardin L, Larkin A, Whitten R, et al. An open vascular simulation course consisting of three one-hour sessions increases the knowledge and technical proficiency of junior surgical residents to that of senior residents. *J Vasc Surg*. 2011;53:28S-29S.
4. Stancu B, Andercou O, Mironiuc A, Andercou A. Combined thrombendarterectomy - still a feasible technique for peripheral arterial occlusive disease in selected cases. *Ital J Vasc Endovasc Surg*. 2010;17(3-S1):239-242.
5. Mironiuc A, Bontea D, Silaghi H, Gherman C, Andercou O, Stancu B, et al. Tratamentul chirurgical al bolii aterosclerotice aorto-iliace. *Chirurgia*. 2008;103(5):565-568.
6. Wilhelm M, Klemm K, Assadian A, Schmidli J, Schumacher H, Merrelaar J, et al. Improve your skills!: Evaluation of a 2.5-day basic course in vascular surgery for surgical trainees. *Chirurg*. 2013;84(2):125-129.

7. Duschek N, Assadian A, Lamont PM, Klemm K, Schmidli J, Mendel H, et al. Simulator training on pulsatile vascular models significantly improves surgical skills and the quality of carotid patch plasty. *J Vasc Surg.* 2013;57(4):1148-1154.
8. Hseino H, Nugent, E, Lee MJ, Hill AD, Neary P, Tierney S, et al. Skills transfer after proficiency-based simulation training in superficial femoral artery angioplasty. *Simul Healthc.* 2012;7(5):274–281.
9. Bismuth J, Donovan MA, O'Malley MK, El Sayed HF, Naoum JJ, Peden EK, et al. Incorporating simulation in vascular surgery education. *J Vasc Surg.* 2010;52(4):1072-1080.
10. Desender LM, Van Herzeele I, Aggarwal R, Vermassen FE, Cheshire NJ. Training with simulation versus operative room attendance. *J Cardiovasc Surg (Torino).* 2011;52(1):17-37.
11. Fann JJ, Caffarelli AD, Georgette G, Howard SK, Gaba DM, Burdon TA. Improvement in coronary anastomosis with cardiac surgery simulation. *Cardiovasc Surg.* 2008;136:1486-1491.
12. Fann JJ, Calhoon JH, Carpenter AJ, Merrill WH, Brown JW, Poston RS, et al. Simulation in coronary artery anastomosis early in cardiothoracic surgical residency training: the boot camp experience. *J Thorac Cardiovasc Surg.* 2010;139:1275-1281.
13. Pandey VA, Wolfe JH. Expanding the use of simulation in open vascular surgical training. *J Vasc Surg.* 2012;56(3):847-852.
14. Woo K, Rowe VL, Weaver FA, Sullivan ME. The results of a needs assessment to guide a vascular surgery skills simulation curriculum. *Ann Vasc Surg.* 2012;26(2):198-204.